

# ceramic implants

**international magazine of** ceramic implant technology



## **research**

Dental implants and  
bone marrow defects

## **case report**

Ceramic implant placement  
in a medically compromised patient

## **industry**

Patent™ —the proven master of zirconia implants



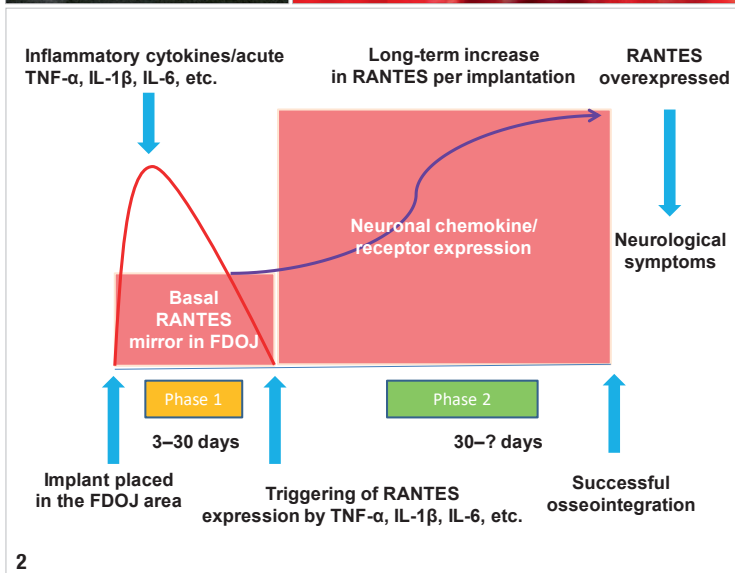
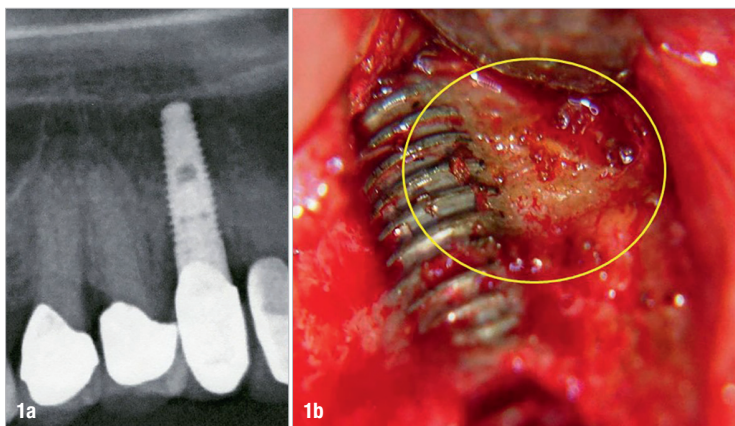
# Dental implants and bone marrow defects

## Evaluation of bone quality by intra-oral ultrasonography

Dr Johann Lechner, Germany

### Introduction

In ceramic implants—**international magazine of ceramic implant technology** *issue 2/2021*, I discussed



**Figs. 1a & b:** Radiograph of an implant. No sign of inflammation in the jawbone (a). Fatty degenerative osteolysis directly attached to the implant and thus not detectable by radiograph (b). **Fig. 2:** This figure shows schematically the sequence of cytokine expression after wound setting by insertion of an implant into a bone area that is already preloaded with chronic inflammation of fatty degenerative bone marrow.

the objective validation of bone quality before implant placement in light of establishing whether the level of mineralisation in the jawbone is sufficient to osseointegrate an implant without any issues and to keep it secure in a stable bone bed for a long time or whether the implant is connected to a bone marrow defect.<sup>1</sup> In this current article, I would like to consider two questions relevant to the situation after implant insertion:

- Was the implant inserted into poorly healed bone?
- Is implant failure directly associated with incomplete wound healing of the implant site and a bone marrow defect around the implant?

### How to forecast the success of dental implants

The measurement of the quantitative ultrasonic transmission velocity (UTV) has been established as an innovative, objective, valid and reliable method for repeated, non-invasive measurements of bone quality before dental implantation.<sup>5</sup> The intra-individual correlation of the UTV values of the maxillary and mandibular lateral regions makes the data easy to interpret. The use of a small UTV device in this study enabled the recording of intra-oral UTV values in a large and heterogeneous patient population. Assessment of alveolar ridge UTV could provide a method for identifying critical bone quality before implant insertion or for monitoring bone healing (mineralisation) after augmentation procedures.<sup>6</sup>

The main advantages of ultrasonic measurement are that it is non-ionising, non-invasive, tolerable and available at relatively low costs. Furthermore, the examination is not a complicated process and can be easily performed by clinicians.<sup>7,8</sup> The new technology of trans-alveolar ultrasonic (TAU) measurement by CaviTAU can reliably identify regions of low mineralisation density in bone marrow cavities with signs of bone marrow defects and collateral chronic ischaemic inflammation.<sup>9,10</sup>

## Implant insertion and bone marrow defects

There is no doubt that dental implantology has achieved a very high reliability and success rate in recent years. Despite this, there is increasing evidence that, in addition to the success of long-term stability, other medical assessment criteria should also be part of the discussion. Further questions on implant insertion arise, such as:

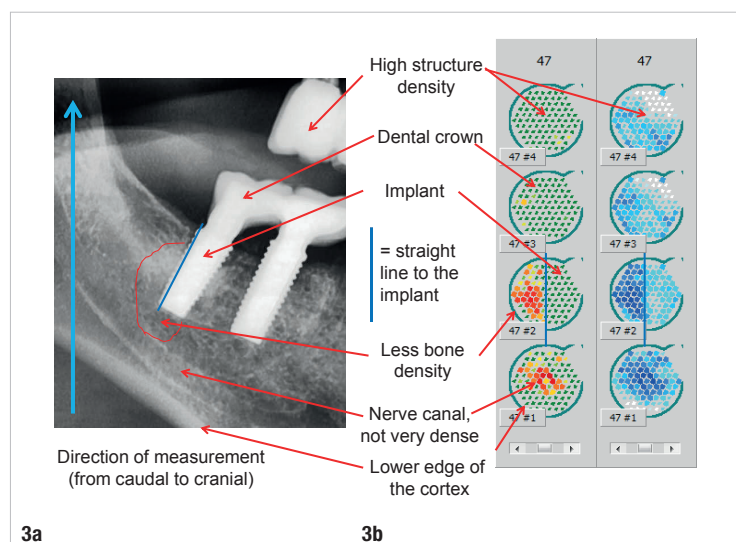
- Are good stability and loading capacity of an implant the only assessment criteria for implant success?
- Is there also undetected silent inflammation arising from fatty degenerative bone marrow defects (fatty degenerative osteonecrosis of the jawbone; FDOJ)?

A clinical case gives the answer to these questions: the panoramic radiograph showed that the implant had healed inconspicuously, hiding that it was directly attached to fatty degenerative morphology (Fig. 1). The overexpression of chemokine RANTES (CCL5) in regions of reduced bone density surrounding implants, as presented in the following case reports, has been described in detail. These FDOJ areas persist as silent or subclinical inflammation without the typical signs of acute inflammation.

In bone resorption in periodontitis and peri-implantitis, the acute cytokines tumour necrosis factor- $\alpha$  (TNF- $\alpha$ ) and interleukin-6 (IL-6) are central to the destructive inflammatory process. A possible titanium intolerance provokes further expression of TNF- $\alpha$  and IL-1 $\beta$  via released titanium particles and increased bone resorption.<sup>3</sup>

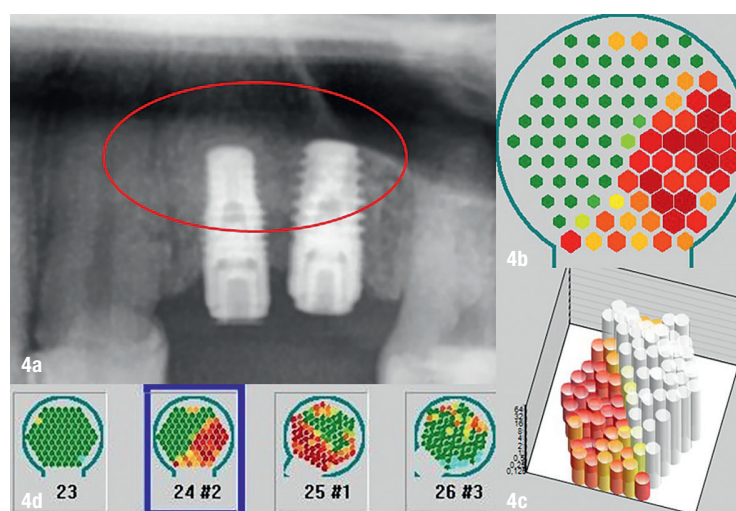
However, beyond this easily accessible therapeutic level, there are other bone resorption processes in the deeper layers of the bone marrow known as bone marrow defects or marrow oedema. This FDOJ morphologically shows bone softening, and TNF- $\alpha$  and IL-6 are far below the levels found in the healthy medullary cavity. In contrast, there is an up to 35-fold overexpression of RANTES.<sup>11</sup> With this chronic RANTES signal transduction, FDOJ appears to represent a unique pattern of inflammation with osteolysis in the body.

Local periodontal production of inflammatory cytokines such as TNF- $\alpha$  and IL-1 $\beta$  or IL-6 dysregulates regulatory and compensatory mechanisms that prevent the formation of implant-related FDOJ in the bone marrow. Arising from an intramedullary overexpression of RANTES, this phenomenon seems to be more widespread than originally thought. However, surgical removal of FDOJ areas can stop the induction of RANTES signalling pathways and thus inhibit the progression of associated symptoms.<sup>11</sup>



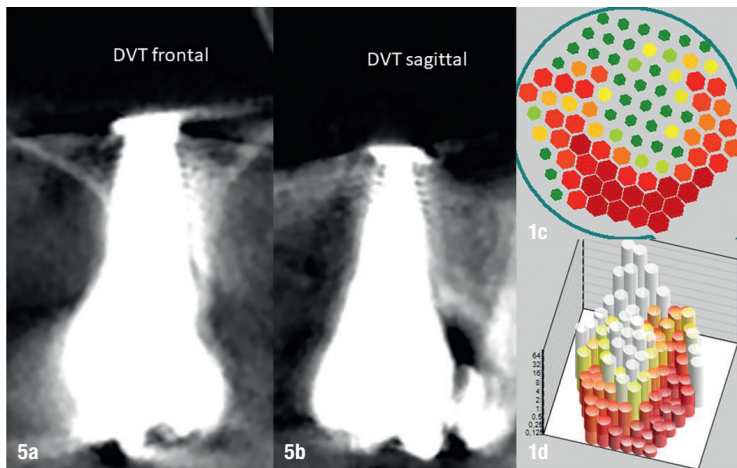
**Figs. 3a & b:** Two ceramic implants in areas #46 and 47 in an unremarkable radiograph (a). CaviTAU measurement in four vertical comparison steps (b).

An implant may be placed in an ischaemic area of subclinical FDOJ because of the radiographically inconspicuous FDOJ morphology and the lack of alternative methods for measuring bone density. Perala et al. demonstrated the induction of TNF- $\alpha$  *in vitro* after co-incubation of native implant material, which ensures that immunogenic particles are released from the materials.<sup>12</sup> With regard to cytokine expression in the context of an implant and the associated phases of healing, analysis during different stages of implantation reveals several new phases of cytokine-triggered signalling pathways. Acute wounding



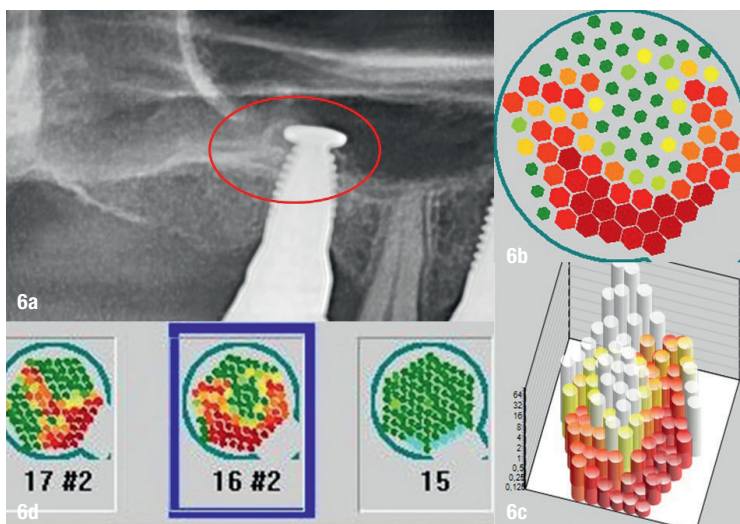
**Figs. 4a–d:** Radiograph showing implants in areas #24 and 25 and inconspicuous bone around the implants (a). CaviTAU image clearly displaying the straight line where the implant (in green) comes into contact with the obviously osteolytic jawbone in red (b). The white columns show the implant, and the red columns indicate the diminished bone density of the directly adjacent jawbone (c). In contrast to the radiograph, the measurement by CaviTAU of the bone density adjacent to the implants displays diminished bone density in red (d).





**Figs. 5a–d:** Frontal and sagittal CBCT images of implant #16. No conspicuous signs of inflammation (**a** & **b**). CaviTAU image of the apical part of the implant in green (green = hard substance), surrounded by suspected osteolytic or osteonecrotic areas in red (red = low bone density; **c**). CaviTAU image of the hard substance of the implant in white, surrounded by suspected osteolytic or osteonecrotic areas in red (**d**).

initiated by implant placement, which induces the release of acute cytokines through surgical trauma, provokes inflammatory cascades of TNF- $\alpha$ , IL-6 and IL-1 $\beta$  expression. TNF- $\alpha$  expression provokes increased secretion of RANTES in the bone surrounding the implant in the medium to long term (Fig. 2).<sup>13–16</sup> The apparent clinical stability of the implant and the radiographic inconspicuousness of the implant lead to the misdiagnosis of an apparently inflammation-free osseointegration.



**Figs. 6a–d:** Radiograph of the ceramic implant placed about nine months before. The radiograph did not give any indication of a possible cause of the atypical facial pain since insertion (**a**). CaviTAU image indicating a relatively high degree of bone loss around the implant in red (**b**). CaviTAU image of the implant in white and the surrounding diminished bone density in red (**c**). According to the CaviTAU measurement, the conspicuous areas with possible osteolysis indicated in red are towards the apical area of implant #16 with clear osteolysis (**d**).

## CaviTAU detects focal inflammation areas around implants that cannot be identified by radiographs

CaviTAU solves the problem by providing reliable ultrasonic imaging of the circumscribed bone density. The measurement is divided into four vertical comparison steps, demonstrated here with reference to Figure 3:

- **Step 1:** The bottom right measurement shows caudal visualisation of the lower cortical margin of the lower jaw, as well as the less dense areas of the infra-alveolar nerve canal in red and dark blue.
- **Step 2:** The measurement shows the dense implant structure in green or light blue and white with a clearly straight delimitation of the distally located red or dark blue indicating reduced mineralisation density and suspected osteolysis.
- **Steps 3 & 4:** In a cranial and vertical direction, the scan shows dense structures in green or white and areas of suspected minor osteolysis or peri-implantitis in light blue.

## Case reports on chronic inflammation around implants and their visualisation

In the following case reports, the reduced bone densities shown by CaviTAU—where the practice procedures allowed—were confirmed with the postoperative findings of RANTES expression measured by the multiplex procedure of light microscopy. Generally speaking, panoramic radiographs do not show findings of reduced bone density and are not sufficient for diagnosis of osteolysis.<sup>17</sup> The focus of these case reports is the metrological evaluation of bone density with CaviTAU used from a diagnostic and a preventive perspective.

### Case 1

The 35-year-old female patient came to our practice with complaints of pressure in areas #24 and 25, into which two titanium implants had been placed. Previously, after several root canal therapies and unsuccessful apicectomies, the teeth had finally been extracted and replaced with titanium implants. On the CBCT scan, the implanting dentist could not see any abnormalities at implants #24 and 25 that could explain the pressure complaints and pulling pain in the implant area. As the patient did not wish to retain the two implants owing to this chronic feeling of pain, she came to our clinic with the request for a more detailed ultrasonic diagnosis of her bone situation in the region of implants #24 and 25.

We performed a measurement of the bone density in the region of implants #24 and 25 with CaviTAU. The

“The use of a small UTV device in this study enabled the recording of intra-oral UTV values in a large and heterogeneous patient population.”

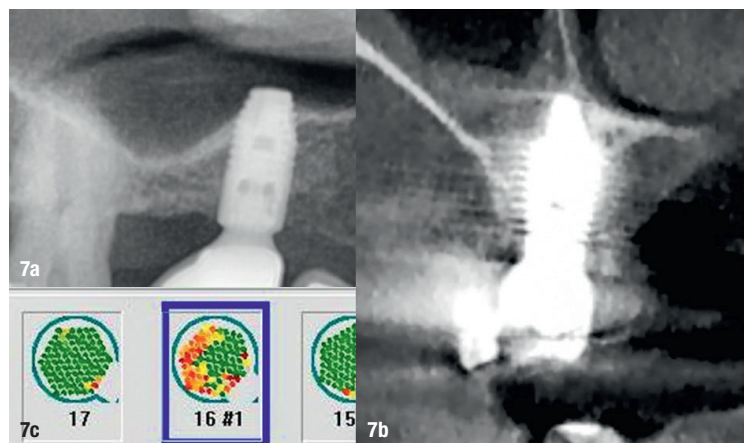
healthy neighbouring teeth, teeth #23 and 26, were also measured, as recommended for a lateral comparison measurement (Fig. 4). The measurement showed the teeth #23 and 26 in green, indicating dense structure. The extensive red area of osteolytic jawbone with clear demarcation of the hard implant proved the patient's complaint pattern. Both implants had been placed in a bone area that had not healed properly, and the remaining FDOJ had led to the patient's neuralgic complaint pattern after implantation.<sup>18</sup> These FDOJ areas remain as silent or subclinical inflammation without the typical signs of an acute inflammation.<sup>19</sup>

This case demonstrates the importance of the question of whether the implants have been inserted into healthy bone. With modern digital radiographic technology, we have a means of digital determination of the bone quantity, that is, whether the bone volume is sufficient for implantation, but no means of digital determination of bone quality, that is, whether the bone is healthy enough for implantation.

The implanting dentist had already tried antibiotics for several weeks without success. Therefore, the only way out was to remove the implants, debride the osteolytic areas and build up healthy bone to enable further implantation in the patient. The financial expenditure for the preceding implantation was thus just as high as the preceding root canal therapies and apicectomies. A quick assessment of the bone density in areas #24 and 25 employing a low-cost ultrasonic measurement with CaviTAU would have led to a considerable cost-saving and a medically safe procedure.

## Case 2

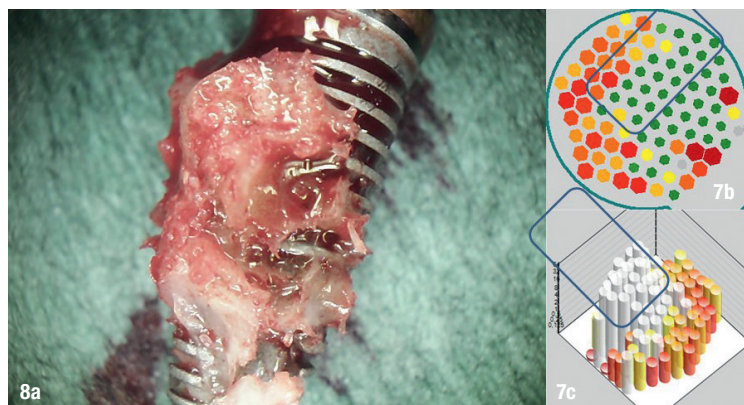
Nine months before, the 57-year-old female patient had received a ceramic implant simultaneously with a sinus lift immediately after extraction of her endodontically treated tooth #16. With the implant fixed, she was not sensitive to biting, but had suffered from chronic pain in the right upper jaw with no apparent cause for the last six months.



**Figs. 7a–c:** Radiograph showing inconspicuous bone tissue around implant #16 (a). The CBCT scan should show the degree of mineralisation of the peri-implant bone environment; however, the hardening artefacts caused by the implant prevented this visualisation (b). CaviTAU image clearly showing red around the implant, indicating an area of reduced mineralisation density (c).

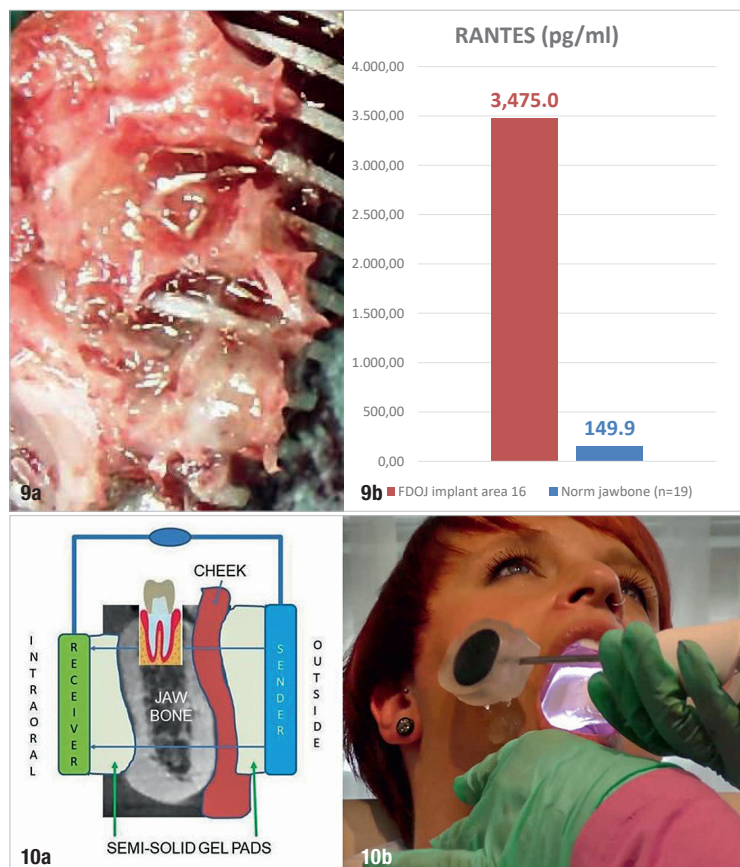
The main problem in practice related to radiographic imaging in implantology is that typical hardening artefacts occur in CBCT scans, caused by ceramic implants in particular but also by titanium implants. The regions between the implants and the implant–bone interface cannot be visually reconstructed correctly for technical reasons (Fig. 5).<sup>4</sup>

Histology was performed of a 0.5 cm sample material of the apical tissue around implant #16 with an older scarring apical granuloma with foreign-body granulomas around partially birefringent foreign material. The sample material consisted predominantly of fibrous connective tissue with foreign-body giant cells partly around birefringent foreign material. Only minimal chronic inflammatory cell infiltration was found.



**Figs. 8a–c:** Post-op photograph of the bone situation around the implant clearly showing the FDOJ tissue attached to the implant (a). Corresponding to this is the 2D view of the hard implant shown in green in CaviTAU with a rectangular outline of the implant and a visualisation of the osteolytic dissolved tissue around the implant bed in red (b). 3D representation of the osteolytic dissolved tissue around the implant bed in red with clear borderlines to the implant, shown in white (c).





**Figs. 9a & b:** Large areas of dissolved bone directly around the implant, as well as fatty parts (a). Local overexpression of RANTES by around 30-fold compared with the standard value of the multiplex analysis (b). **Figs. 10a & b:** The sender and receiver are in a fixed coplanar position (a bar connects the sender and receiver). There are semi-solid gel pads between the sender and the cheek on the outside of the mouth and between the receiver and the alveolar ridge in the intra-oral position. A trans-alveolar ultrasonic impulse is sent from the sender to the receiver (blue arrows; a). Positioning of the sender (outside) and receiver (intra-oral) in the lower jaw (b).

The peri-implant tissue showed not only the typical FDOJ softening but also the overexpression of RANTES. This further validated the pathological imaging by CaviTAU. It appeared that further inflammatory signalling cascades—primarily based on RANTES messenger substances—had been provoked by the insertion of the implant and the directly associated wound healing. (Fig. 6).

### Case 3

The 57-year-old female patient had suffered from migraines, but only on the right side, and atypical facial pain, in her upper right jaw only, since the implant placement.

Histology of a medullary tissue sample from region #16 found exclusively fatty marrow and necrobiotic changes and areas of mucinous degeneration as well as small oil cysts. It also found small areas of fibrosis. The findings

were altogether consistent with changes related to FDOJ (Fig. 9).

### Conclusion

Our case studies demonstrate the immunological relationship between implants and FDOJ. The extent to which increased expression of RANTES derived from FDOJ areas contributes to immune-mediated disease is difficult to determine. Our cases provide evidence for the possible interaction between implants, RANTES signalling and general health. A comprehensive understanding of the complex networks described in our cases requires further research. Removal of implants and surgical removal of surrounding FDOJ areas can reduce RANTES overexpressed signalling pathways, potentially reducing inflammatory input and associated symptoms.

Owing to the insufficient imaging of the mineralisation levels in the bony implant environment in panoramic radiographs and the unavoidable hardening artefacts in CBCT scans, a considerable part of the bone marrow in the jaw cannot be correctly immunologically assessed. These assessment criteria in implantology can be measured by CaviTAU ultrasonography (Fig. 10).

After extraction of implants and removal of surrounding FDOJ areas, the silent inflammation may remain in the jawbone in case of incomplete debridement and poor bone healing might occur. This situation is then also often responsible for failure of the subsequent implantation or even for immediate ceramic implantation. For future successful implant surgery, prior measurement of the bone density and thus a determination of the metabolic situation in the jawbone is therefore essential for overall immunological safety for the patient and the treatment success for the dentist. For unexplained pain as in our described case reports, the easy-to-use and radiation-free CaviTAU is available to detect radiographically undetectable silent inflammation.



### contact

#### Dr Johann Lechner

Praxisklinik Ganzheitliche ZahnMedizin  
Grünwalder Str. 10  
81547 München, Germany  
drlechner@aol.com  
www.dr-lechner.de

## Master of dentistry: The PAPER® Dental Implant System

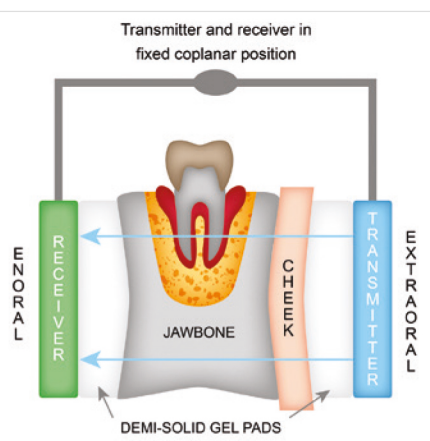
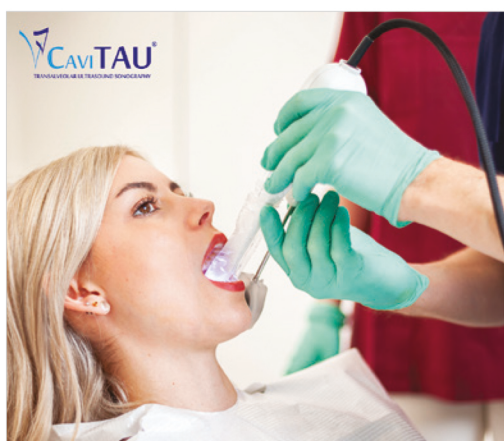The PAPER® Dental Implant System is a revolutionary new concept in dental implantology. It is designed to provide a secure and stable foundation for dental restorations, while also promoting natural bone growth and healing. The system consists of a series of interconnected components, including a base implant, a neck, and a crown. The base implant is made of a highly durable, biocompatible material, and is designed to be inserted into the jawbone. The neck is made of a soft, flexible material, and is designed to provide a natural-looking appearance. The crown is made of a high-quality ceramic material, and is designed to provide a natural-looking appearance. The PAPER® Dental Implant System is a truly innovative solution for dental implantology, and is sure to revolutionize the way we think about dental implants.



## CaviTAU

### New insight into an underrecognised entity

Why do implants fail? Why do more and more people become chronically ill? Is an undetected disease “silent inflammation of the jawbone” behind it? Many questions, one modern answer: the digital-quality determination of bone density through ultrasound sonography—CaviTAU®. Such, the dentist localises chronic and pathogenetic inflammation patterns, cleans them up




CaviTAU® application with LED gel pad and schematic representation of transalveolar sonography.

in surgical “Jawbone Detox steps” and thus turns from a dentist into a systemic-immunologically oriented and integrative Oral Physician.

With the newest version of the english book *Cavitation osteonecrosis in jawbone* by Dr Johann Lechner, you will be guided in over 390 pages, with 120 illustrations and

over 200 literature citations through all the science behind CaviTAU®. The book can be ordered online at the website [www.icosim.de](http://www.icosim.de).

**CaviTAU • Germany • +49 89 244154460 • [www.cavitau.de](http://www.cavitau.de)**



- ◆ **Helping localization of silent inflammation in jawbone.**
- ◆ **Disruptive new ultrasound technology for dentistry findings.**
- ◆ **Checking your implantation success preoperative.**



**MADE IN GERMANY**

**ORDER NOW:**  
[shop.cavitaude.de](http://shop.cavitaude.de)

**CONTACT:**  
[office@cavitaude.de](mailto:office@cavitaude.de)

**MORE INFORMATION:**  
[www.cavitaude.de](http://www.cavitaude.de)

