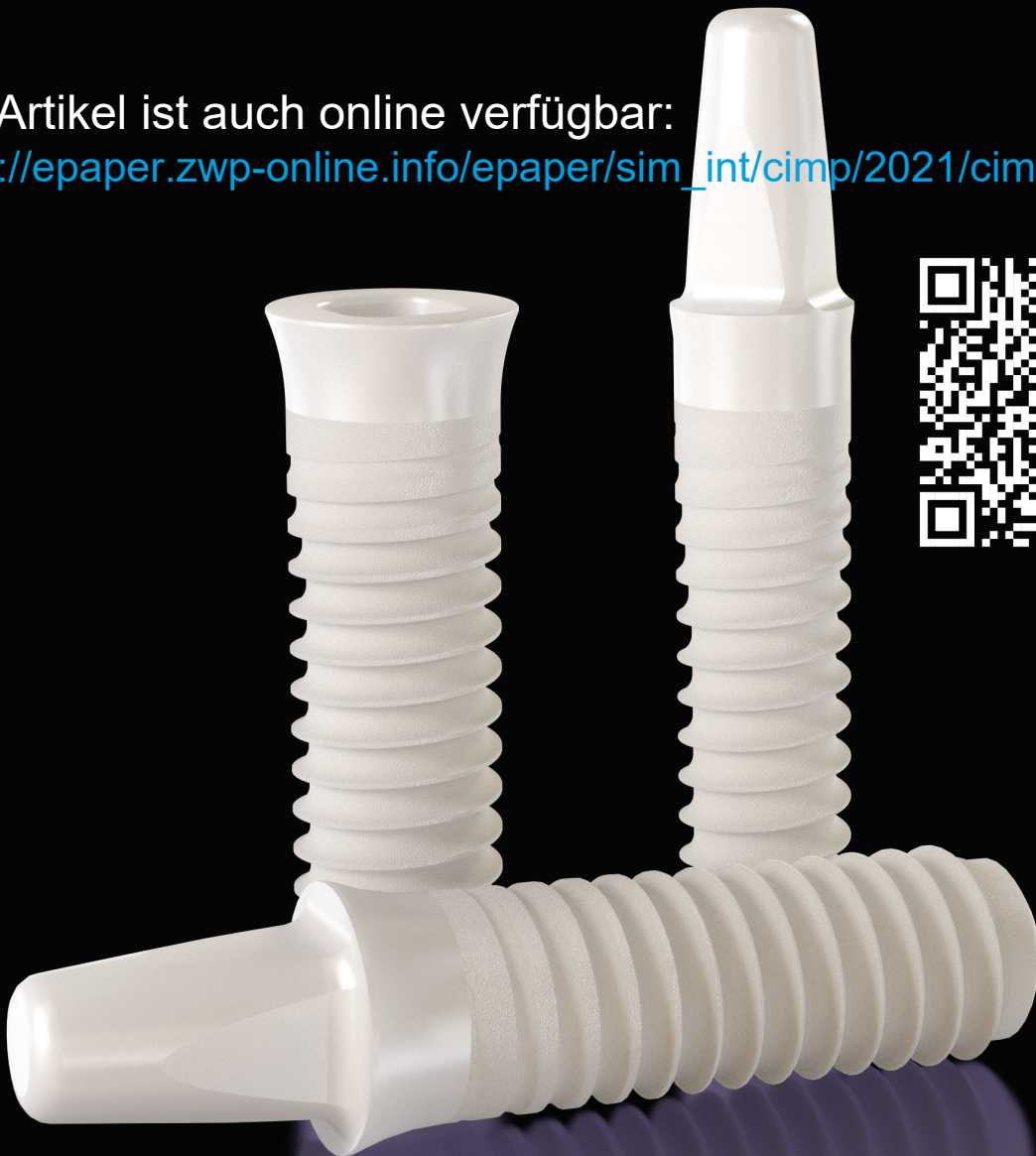

# ceramic implants

**international magazine of** ceramic implant technology

Der Artikel ist auch online verfügbar:

[https://epaper.zwp-online.info/epaper/sim\\_int/cimp/2021/cimp0221#8](https://epaper.zwp-online.info/epaper/sim_int/cimp/2021/cimp0221#8)



## **research**

Room for improvement

## **case report**

Restoring aesthetics in the mandible

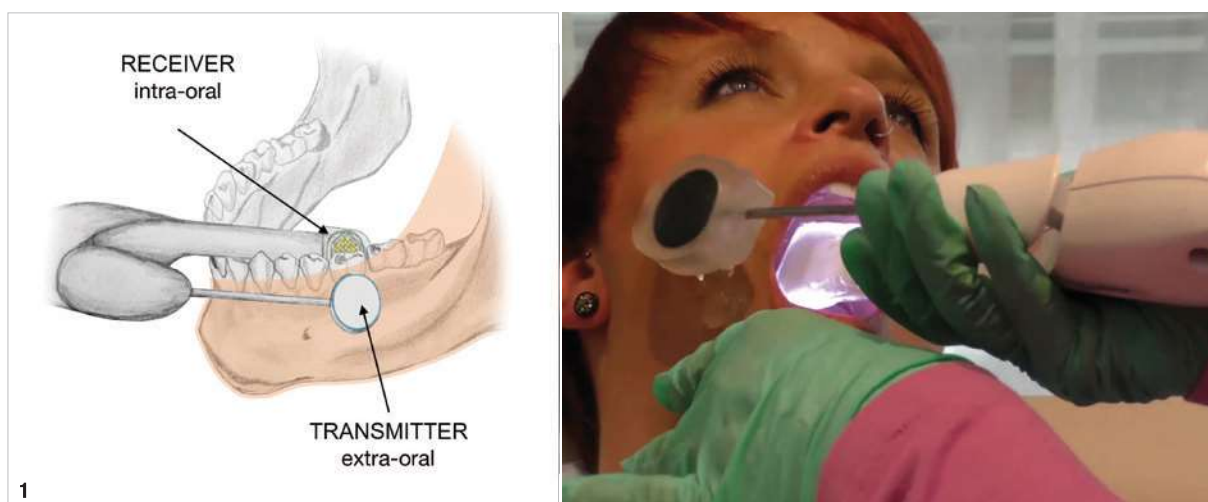## **events**

First JCCI held with great success



# Measuring bone density by intra-oral ultrasound for secure implant insertion

Dr Johann Lechner, Germany



**Fig. 1:** Schematic representation of the positioning of the transmitter and receiver (left). Practical application of CaviTAU® with intra-oral measurement, using LED light for exact definition of the measurement area (right).

## Introduction

In the medical field, ultrasonography is widely used to image various types of soft tissue. In principle, images of structures in the body are generated by analysing the reflection of ultrasonic waves. To derive useful information concerning the status of jawbone, different ultrasonic techniques must be employed, as the ultrasonic waves are almost completely reflected at the bone–soft-tissue interface. The *in vivo* measurement of ultrasonic velocity in human cortical bone was introduced as a rapid, reliable and non-invasive method which could be used to analyse the mechanical properties of bone.<sup>1</sup> Is a newly available ultrasonic device for the radiation-free measurement of bone density (CaviTAU®; Digital Dental & Healthcare Technology) suitable for visualising the condition of jawbone density?

## Is the jawbone ready for implant insertion?

Researchers have reported microscopically proven chronic ischemic/inflammatory or fatty degenerative osteonecrosis of the jawbone (FDOJ);<sup>2</sup> FDOJ was found in >50% of 154 clinically and radiographically unremarkable edentulous jaw areas into which dental implants were to be placed. The following question is therefore justified:

can aseptic bone necrosis pose a risk to implant placement?<sup>3</sup> The currently available literature offers an insight into anecdotal reports of “poor quality” alveolar bone discovered during implant surgery in edentulous sites. This poses a risk for the uninterrupted osseointegration of implants.<sup>4</sup> Aseptic bone necrosis has been reported after surgery, trauma and immunosuppressive therapy.<sup>5,6</sup> The evolution of aseptic necrosis is documented in the maxillomandibular region, particularly after osteotomies.<sup>7,8</sup> It has been found that micromotion of implants in soft bone is consistently high and that this can result in failed osseointegration. Scientists—such as those who have reported FDOJ from the Division of Periodontics of the University of Maryland School of Dentistry in Baltimore in the US—speak of the phenomenon of a chronic ischemic/inflammatory or FDOJ. This pathology is thus internationally recognised and was first included in the tenth revision of the International Statistical Classification of Diseases under “aseptic ischemic osteonecrosis”.

## Assessing stability of the bone bed with ultrasound

Whether implants can be embedded in the jaw for extended periods depends primarily on the condition of the bone. In the anterior of the lower jaw, conditions are

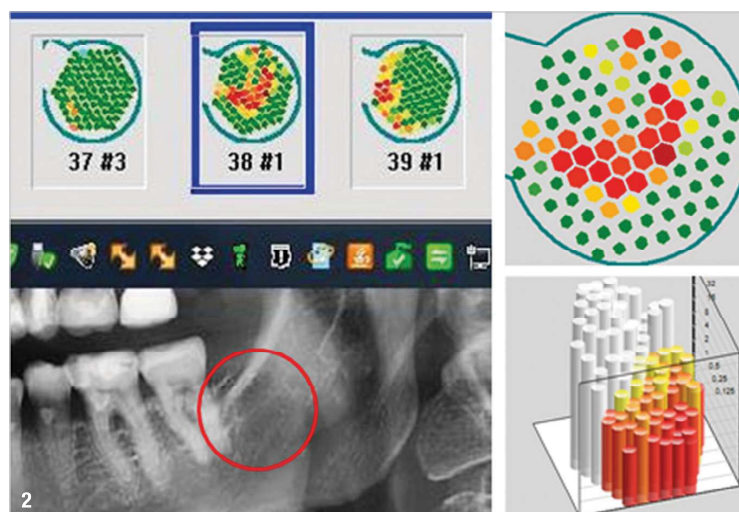
usually ideal. However, in the upper jaw, the bone is naturally less dense. The dentist often only notices whether an implant will stay in place here when drilling or when cutting the thread for the implant into the bone, and even this impression can be deceptive: "There is no reliable method for predicting the success of dental implant insertion before the dental procedure," according to Prof. Robert Sader from the clinic for oral and facial plastic surgery at the Frankfurt university hospital in Germany. One solution is determining the density of the bone using ultrasound. This is because the propagation of ultrasonic waves in bone tissue depends on its density: the more stable the bone, the faster the waves move through it. Scientists at Johannes Gutenberg University Mainz have now investigated for the first time whether the method also allows conclusions to be drawn on the condition of the jawbone. Prof. Bilal Al-Nawas from the clinic for oral and maxillofacial surgery has investigated ultrasonic transmission velocity (UTV) in the lower jaw and pelvic bone of pigs. The results indicate that UTV is an accurate measurement of the level of mineralisation: bone sections with a critical bone density that would prohibit implant insertion were detected by the method in 75% of cases. Thus, determining the quality of the bone in the jaw with the help of ultrasound may even be more effective than radiography.<sup>9</sup> Torque and UTV were used to assess the bone implant sites in these studies.<sup>10</sup> UTV can be used to analyse the mechanical properties of the teeth after *in vitro*, *in situ* and *in vivo* loading.<sup>11</sup>

### Is there an intra-oral technique to measure bone density?

The fundamental suitability of ultrasound for determining bone density and thus the length of time implants are in place has already been scientifically validated.<sup>9–11</sup> With ultrasonic devices, dentists can check jawbone quality to predict the success of dental implant insertion. The innovative CaviTAU® is a suitable ultrasonic device for transferring the mentioned findings into routine daily practice: CaviTAU® therefore offers application-oriented reliability for dental implantologists and prevents premature implant loss.<sup>12</sup>

### What is CaviTAU®?

CaviTAU® generates an ultrasonic wave and passes that wave through the jawbone. This wave is produced by an extra-oral transmitter and then detected and measured by a receiving unit that is positioned intra-orally. Both parts (i.e. the sender and receiving unit) are fixed in a parallel position using a single handpiece. The size of the CaviTAU® receiving unit is configured such that it may be easily placed inside the mouth of a patient. CaviTAU® uses 91 piezoelectric elements that are arranged hexagonally. The jawbone must be positioned between the two parts of the measuring unit. With respect to the parts

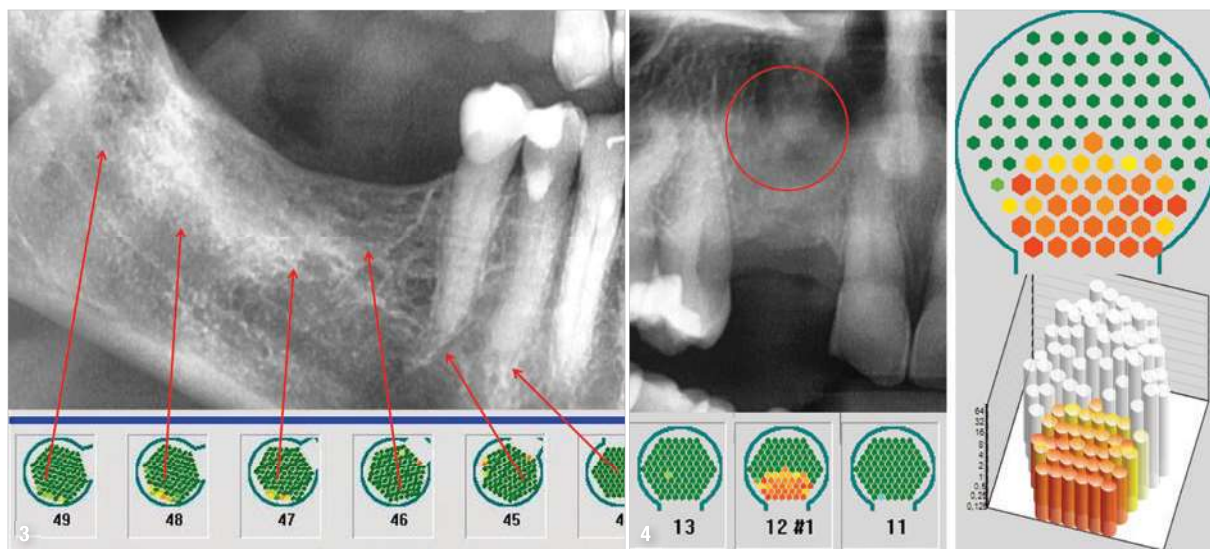


**Fig. 2:** Example of an inconspicuous radiographic image in area #38 (red circle). In contrast, measurement of bone density in area #38 compared with healthy tooth #37 (top left) with ultrasound shows conspicuous red areas in 2D and 3D representation (right).

of the measuring unit to be placed inside the patient's mouth, the acoustic coupling between those parts and the alveolar ridge is performed with the aid of a semi-solid gel. The contact between the jawbone and both the extra-oral ultrasonic transmitter and intra-oral ultrasonic receiver (Fig. 1, left) is optimised and individualised using a special ultrasonic gel cushion that was developed for this purpose. The results are shown on a colour monitor that displays different colours depending on the degree of attenuation. Thanks to the latest computerised miniaturisation of the measuring units, CaviTAU® now offers a wide range of applications. The CaviTAU® display is able to capture the following physical structures in the dentoalveolar region, with the corresponding colour variations of 91 colour columns per cm<sup>2</sup>: (a) solid bone in the marginal cortical area (green or white/light blue); (b) healthy medullary cancellous bone (green or white/light blue); (c) chronic inflammatory medullary cancellous bone with fatty degenerative components (red or black/dark blue); (d) fatty nerve structures (yellow/light blue); and (e) extremely dense and complex structures such as teeth, implants and crowns (green or white/light blue; Fig. 2).

### How to forecast the success of dental implants

The measurement of the quantitative ultrasonic transmission rate (UTV) has been established as an innovative, objective, valid and reliable method for repeated, non-invasive measurements of bone quality before dental implantation.<sup>9–12</sup> The use of a small UTV device in this study enabled the recording of intra-oral UTV values in a large and heterogeneous patient population.<sup>12</sup> Assessment of alveolar ridge UTV could provide a method for identifying critical bone quality before implant insertion or for monitoring bone healing (mineralisation) after



**Fig. 3:** Good example of a perfect state of mineralisation in a lower jawbone, which is characterised by widespread green colouration in CaviTAU® and is suitable for a prospectively unproblematic insertion of implants. This finding is consistent with good conditions for a long implant lifetime. **Fig. 4:** Example of an inconspicuous radiographic image in area #12 (red circle). In contrast, measurement of bone density in area #38 compared with healthy neighbouring teeth #13 and 11 (below left) with ultrasound shows conspicuous red areas in 2D and 3D representation (right).

augmentation procedures.<sup>13</sup> The main advantages of ultrasound are that it is non-ionising, non-invasive, tolerable and available at relatively low costs. Furthermore, the examination is not a complicated process and can be easily performed by clinicians.<sup>14</sup> CaviTAU® was additionally and specifically developed to detect and avoid traumatic defective jawbone areas or non-exposed early-stage bisphosphonate-induced osteonecrosis at implantation sites. For more information on this relatively unknown problem area, please also refer to our own PubMed-indexed publication.<sup>15</sup>

### Does CaviTAU® display load-free jawbone for non-problematic and durable implant insertion?

Case 1: will implant insertion be successful in these jaw areas, and will implants last for a long time? The answer is yes (Fig. 3). Case 2: will implant insertion be successful in this jaw area,<sup>12</sup> and will implants last for a long time? The answer is no (Fig. 4).

### Conclusion

The newly developed CaviTAU® ultrasonography device is able to detect and localise diminished bone density caused by the fatty degenerative dissolution of medullary trabecular structures in the jawbone (FDOJ).<sup>16</sup> As other studies have confirmed,<sup>17,18</sup> ultrasonography is a low-cost and efficient means of assessing jawbone health, and this has been replicated with the use of the new CaviTAU® device presented here. This study established a new value using CaviTAU® which provides a reliable indicator of poor bone quality, rendering the device a useful tool for treatment planning strategies in implantology,

as well as for fostering cooperation among professionals when assessing or treating osteo-immunological disease and linking such disease with the immune system. CaviTAU® thus provides a non-harmful alternative to the use of X-ray irradiation, which is increasingly being criticised,<sup>19,20</sup> particularly in view of more stringent radiation protection laws.<sup>21</sup> CaviTAU® represents a novel type of imaging acquisition process in dentistry and offers the ability to non-invasively assess hidden FDOJ in the human jawbone. CAVITAU® displays load-free jawbone for unproblematic and permanent implant insertion. Measuring bone density before implantation could avoid failures and protect dentists and patients from the early loss of implants in the daily practice.



### contact



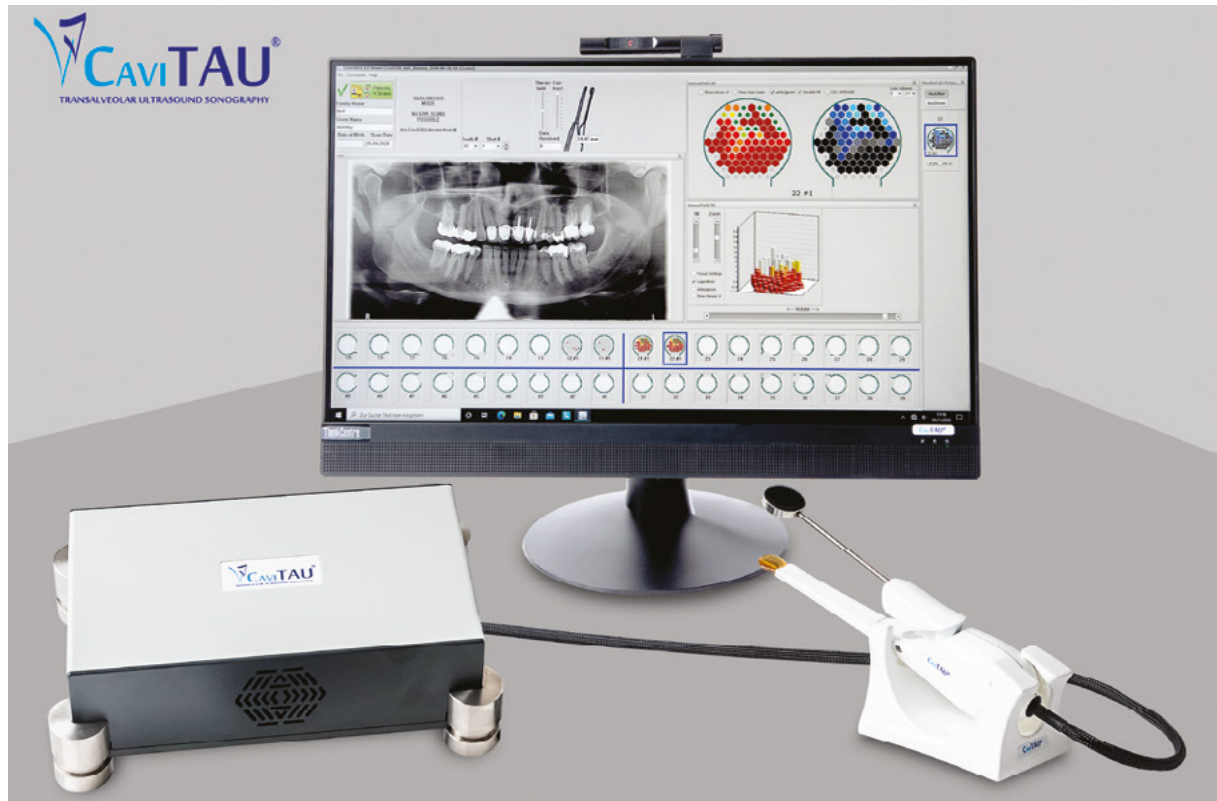**Dr Johann Lechner**  
Praxisklinik Ganzheitliche ZahnMedizin  
Munich, Germany  
drlechner@aol.com  
www.dr-lechner.de

# The radiation-free view into the jawbone

The newly developed CaviTAU® is an imaging ultrasound technique for displaying bone density & quality in the jaw area. CaviTAU® therefore provides implantologists with practice-relevant information on implant success. Ultrasound-based imaging is a safe and minimally invasive technology in medicine. CaviTAU® penetrates solid and healthy bone tissue faster than structurally damaged bone tissue. Alveolar cancellous bone pathologies with low bone density can be safely assessed with the CaviTAU® technique of trans-alveolar ultrasonography (TAU).

CaviTAU® measurement results are displayed on a colour monitor and determine bone density with different colours. Digital X-ray technology determines the available bone quantity for the implantologist and Digital CaviTAU® technology determines the available bone quality for the implantologist—both procedures together ensure implant success.

**CaviTAU® • Germany • +49 89 90421762 • [www.cavitau.de](http://www.cavitau.de)**

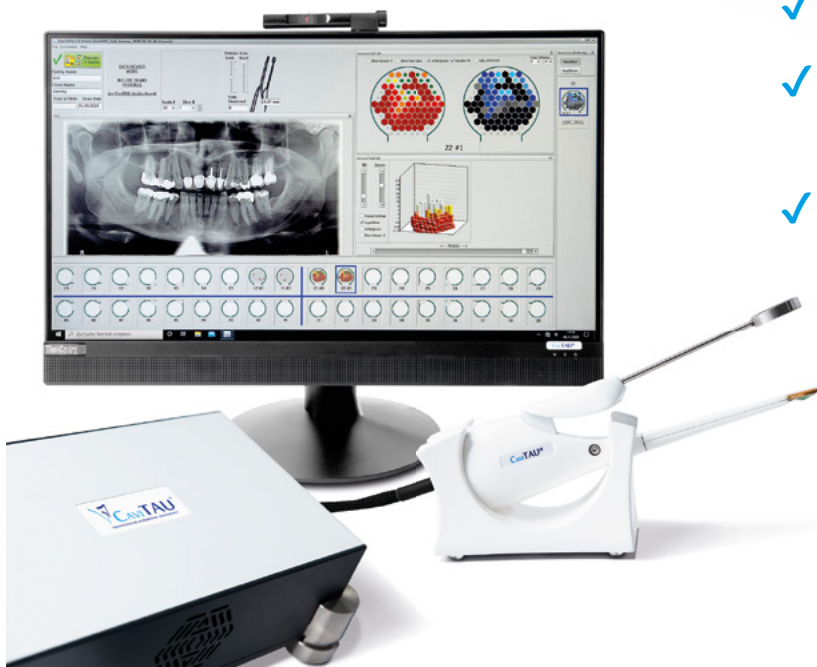

**CaviTAU®**  
TRANSLVEOLAR ULTRASOUND SONOGRAPHY

## Identification of jawbone cavities

- ✓ Helps detoxify the jawbone
- ✓ Preoperative assurance of the implant result
- ✓ Reveals focal areas of inflammation around implants

**Register & Order:**  
**[SHOP.CAVITAU.DE](http://SHOP.CAVITAU.DE)**



CaviTAU®

Call: +49 89 244 15 44 60  
[office@cavitau.de](mailto:office@cavitau.de)  
[www.cavitau.de](http://www.cavitau.de)